



SECOND MODULE

SURFACE ANATOMY



This module designed in surface anatomy to give the students a good knowledge about the surface anatomy, planes, vertical lines. so all this information will made the student in the future when he become assistant have a good communication with the medical staff.



Central Idea :-

Central idea of this module include

- . Planes of body
- . Vertical lines

Instructions:- •

- 1- Study the over view very well . •
 - 2- Identify the aims of modules . •
- . •

Performance Objectives

After studying the first module , the student will be able to:- •

1-Recognize the planes of the body . •

2-Identify the vertical lines •

TABLE 1.1**Orientation and Directional Terms**



TERM	DEFINITION	EXAMPLE
Superior (cranial)	Toward the head end or upper part of a structure or the body; above	
Inferior (caudal)	Away from the head end or toward the lower part of a structure or the body; below	

TABLE 1.1**Orientation and Directional Terms**

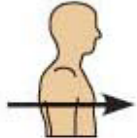
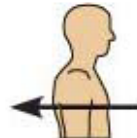
TERM	DEFINITION	EXAMPLE
Ventral (anterior)*	Toward or at the front of the body; in front of	
Dorsal (posterior)*	Toward or at the back of the body; behind	

TABLE 1.1**Orientation and Directional Terms** *(continued)*

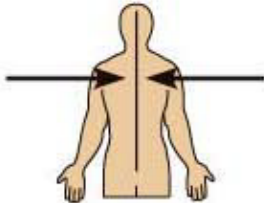
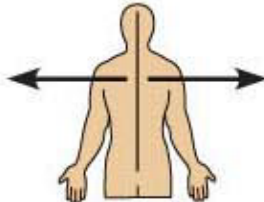

TERM	DEFINITION	EXAMPLE
Medial	Toward or at the midline of the body; on the inner side of	
Lateral	Away from the midline of the body; on the outer side of	
Intermediate	Between a more medial and a more lateral structure	

TABLE 1.1**Orientation and Directional Terms** *(continued)*

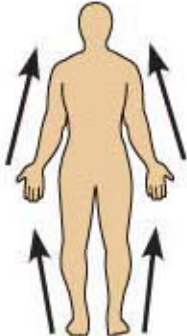
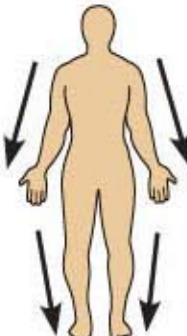
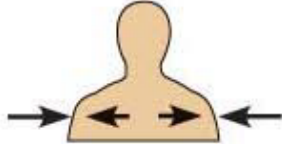
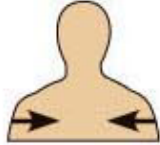
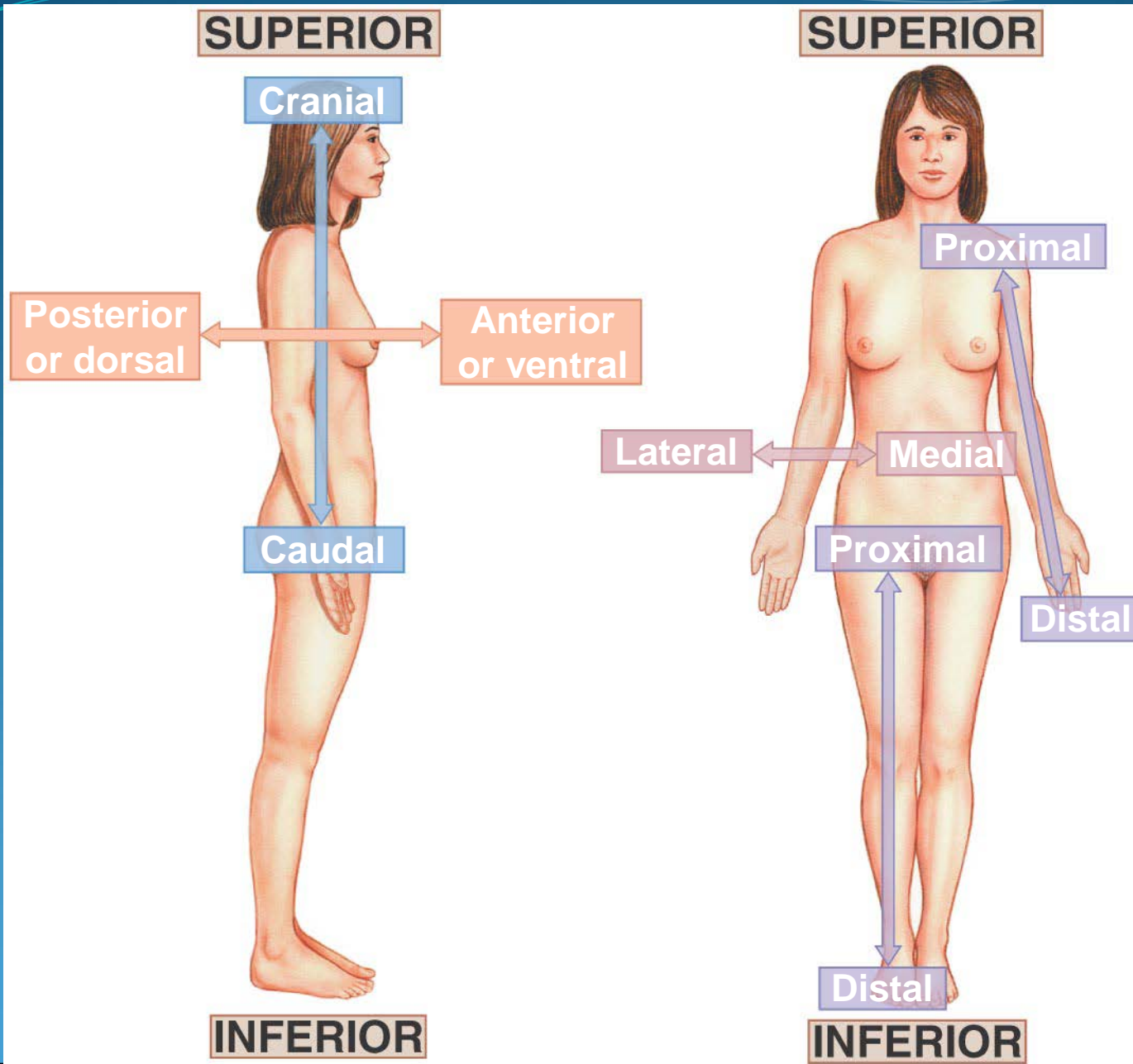
TERM	DEFINITION	EXAMPLE
Proximal	Closer to the origin of the body part or the point of attachment of a limb to the body trunk	
Distal	Farther from the origin of a body part or the point of attachment of a limb to the body trunk	

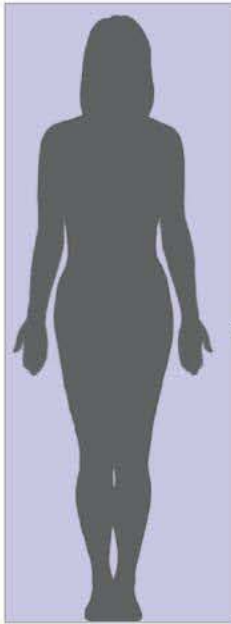
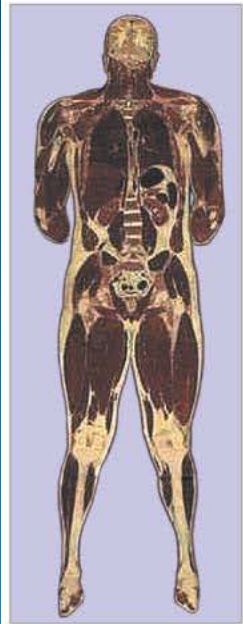TABLE 1.1**Orientation and Directional Terms** *(continued)*

TERM	DEFINITION	EXAMPLE
Superficial (external)	Toward or at the body surface	
Deep (internal)	Away from the body surface; more internal	

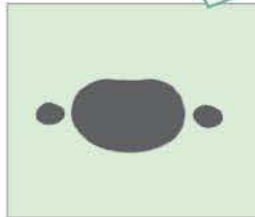
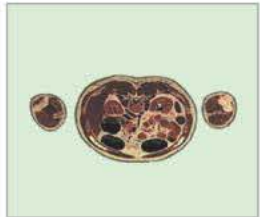Directional Terms



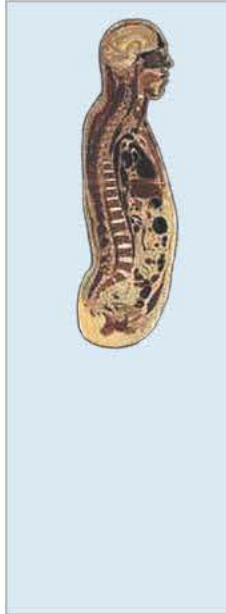
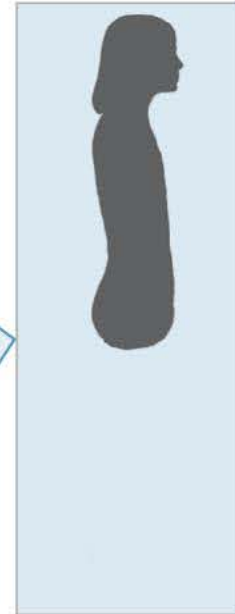
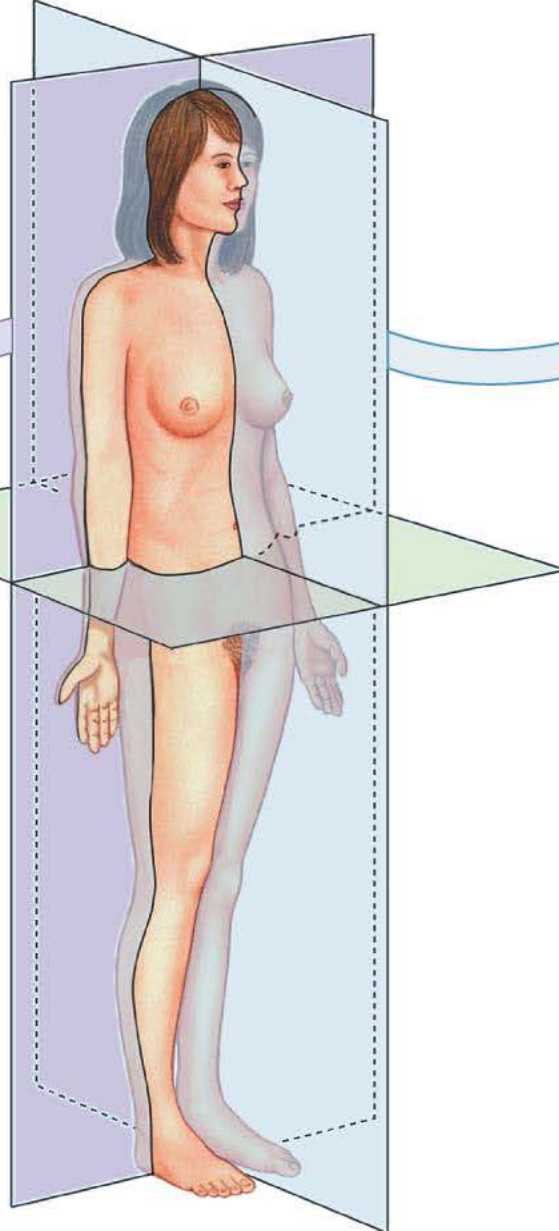
Planes of Section



Frontal plane



Transverse plane



Sagittal plane

Planes of body:-

Plane:-Any imaginary flat surfaces that pass through the human body to divided into two halves. •

1)**FRONTAL** (or coronal):- separates the body into Anterior and Posterior parts •

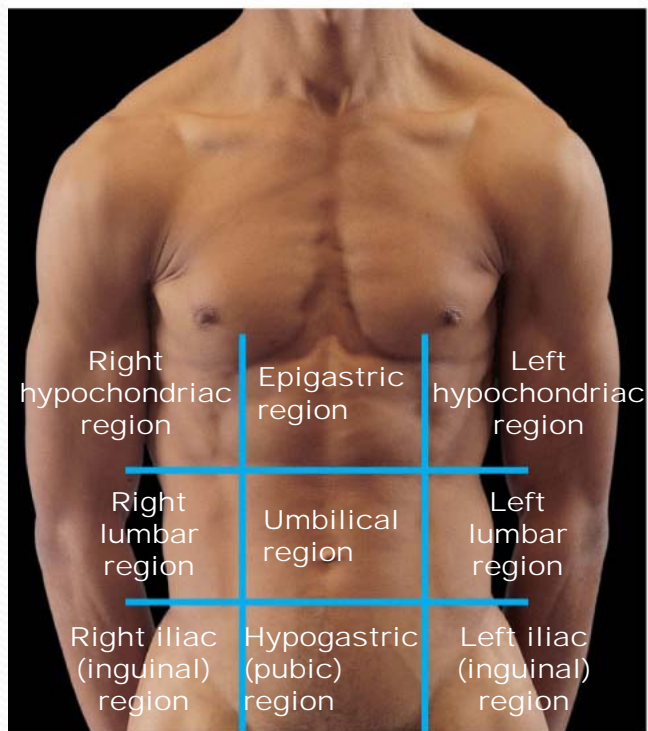
2)**MEDIAN** (or midsagittal) :-separates body into equal Right and Left parts

3)**HORIZONTAL**:- separates the body into Superior and Inferior parts

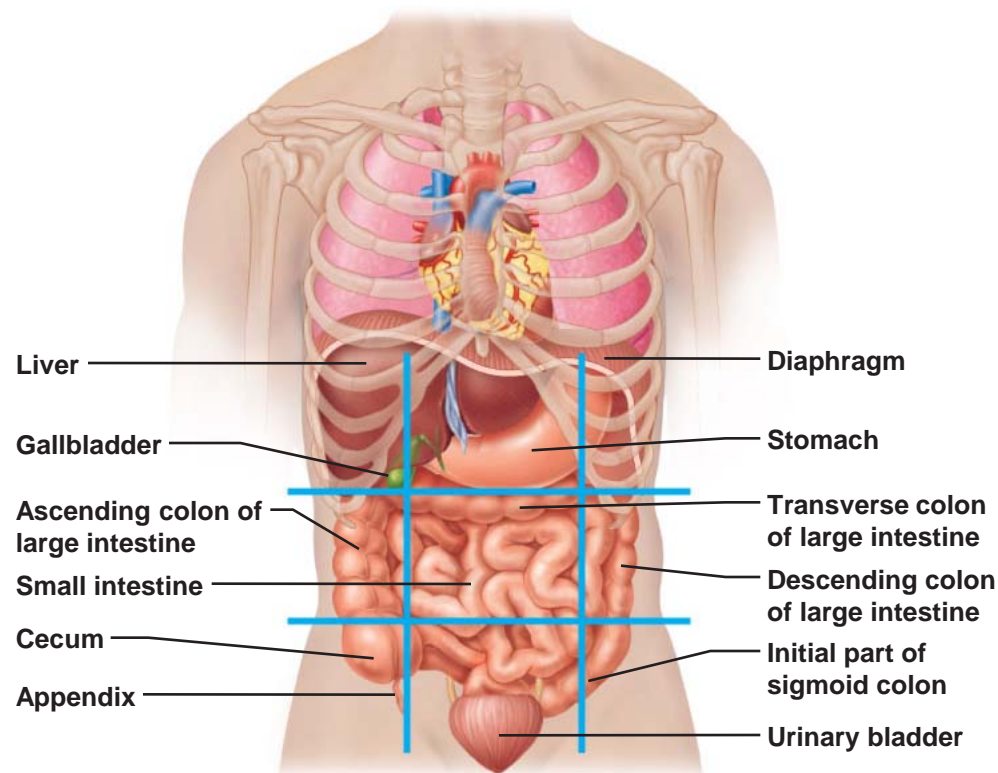
4)**SAGITTAL**:- any plane parallel to the median plane separate body into un equal Right and Left.

Abdominopelvic Regions

Nine divisions used primarily by anatomists •



(a) Nine regions delineated by four planes



(b) Anterior view of the nine regions showing the superficial organs